

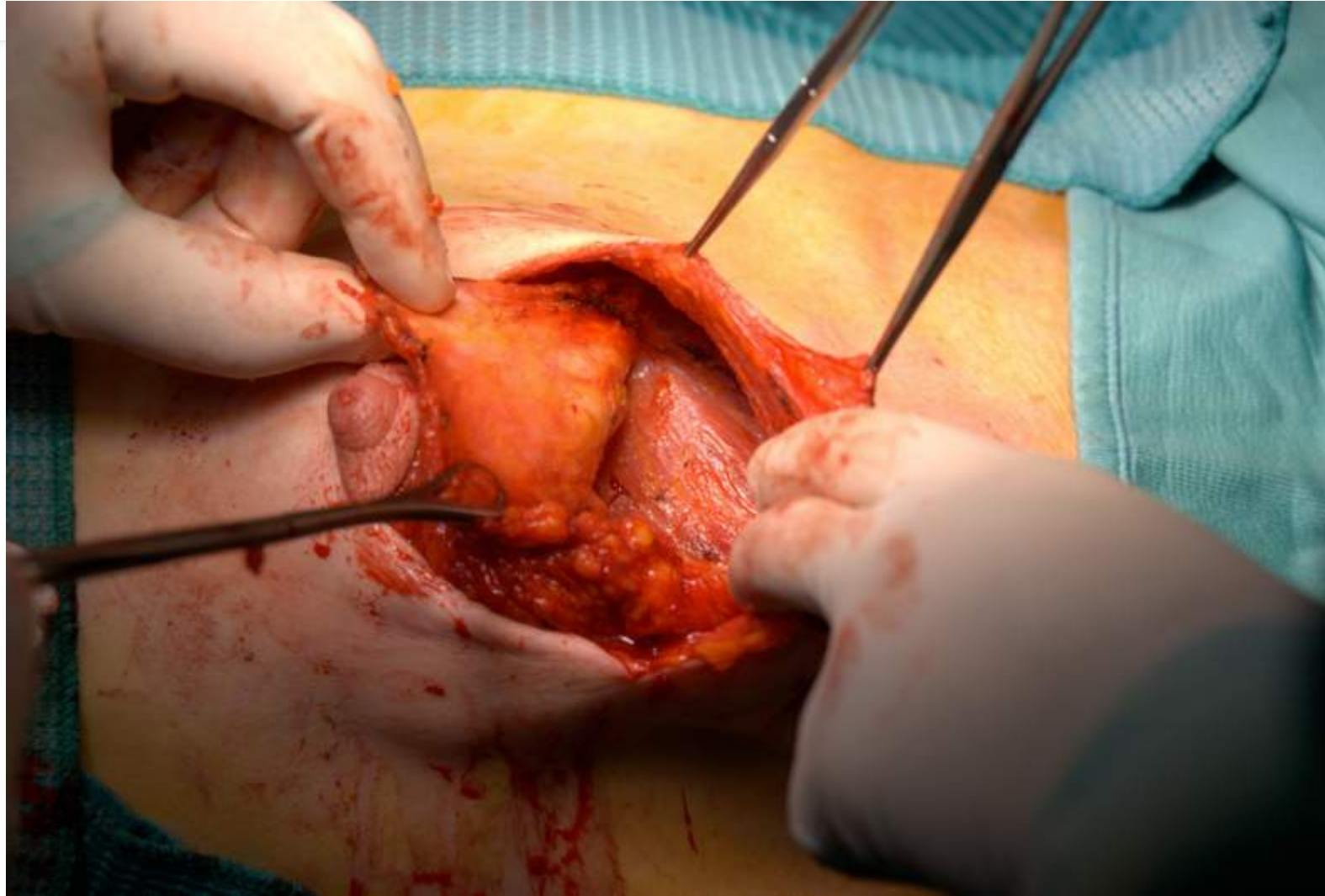
Subpectoral breast  
reconstruction with  
Native<sup>®</sup> ADM

Photos: courtesy of Dr. Glenda G. Caputo

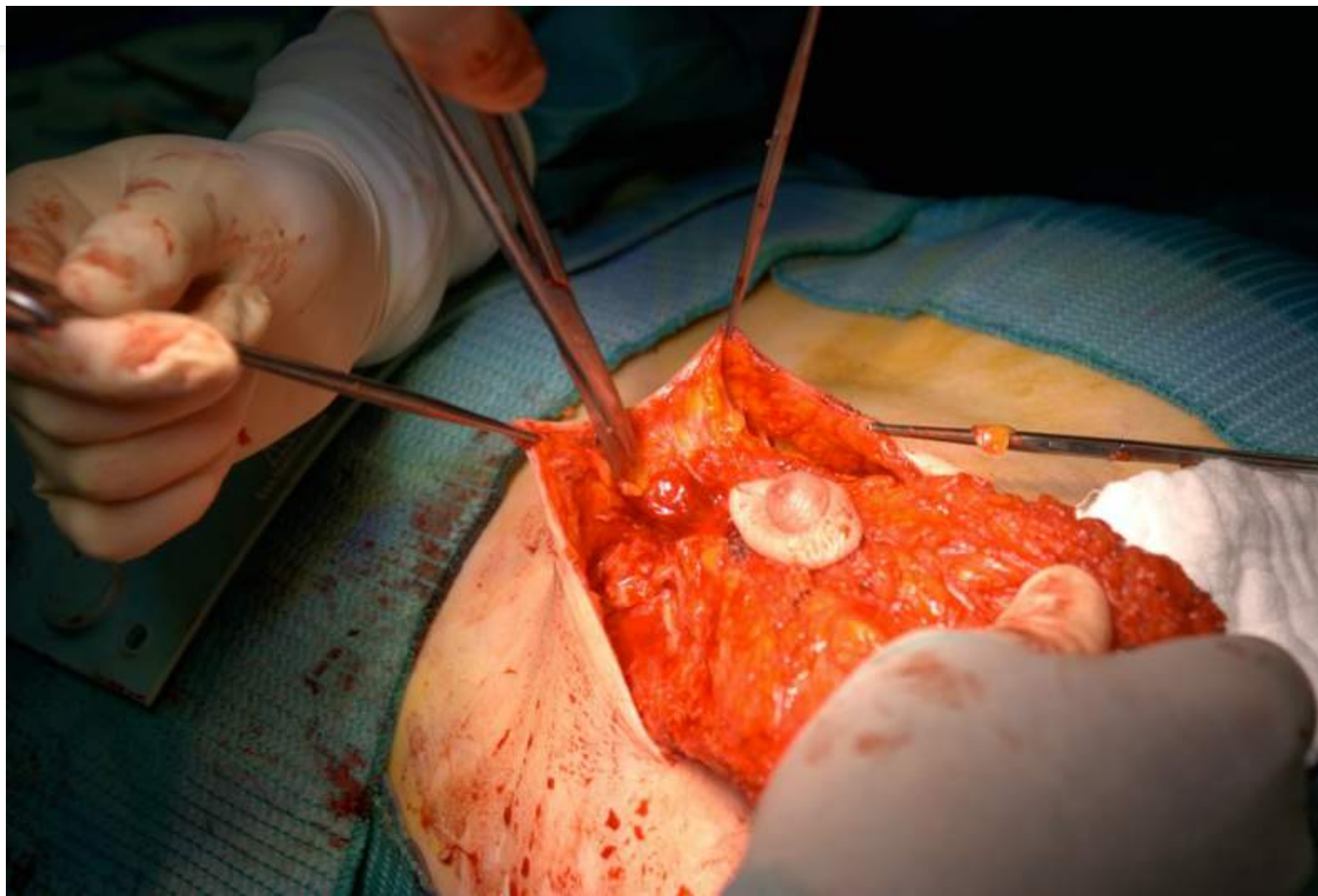Copyright:

**DECO**med  
MARKETING AND TRADE S.R.L.

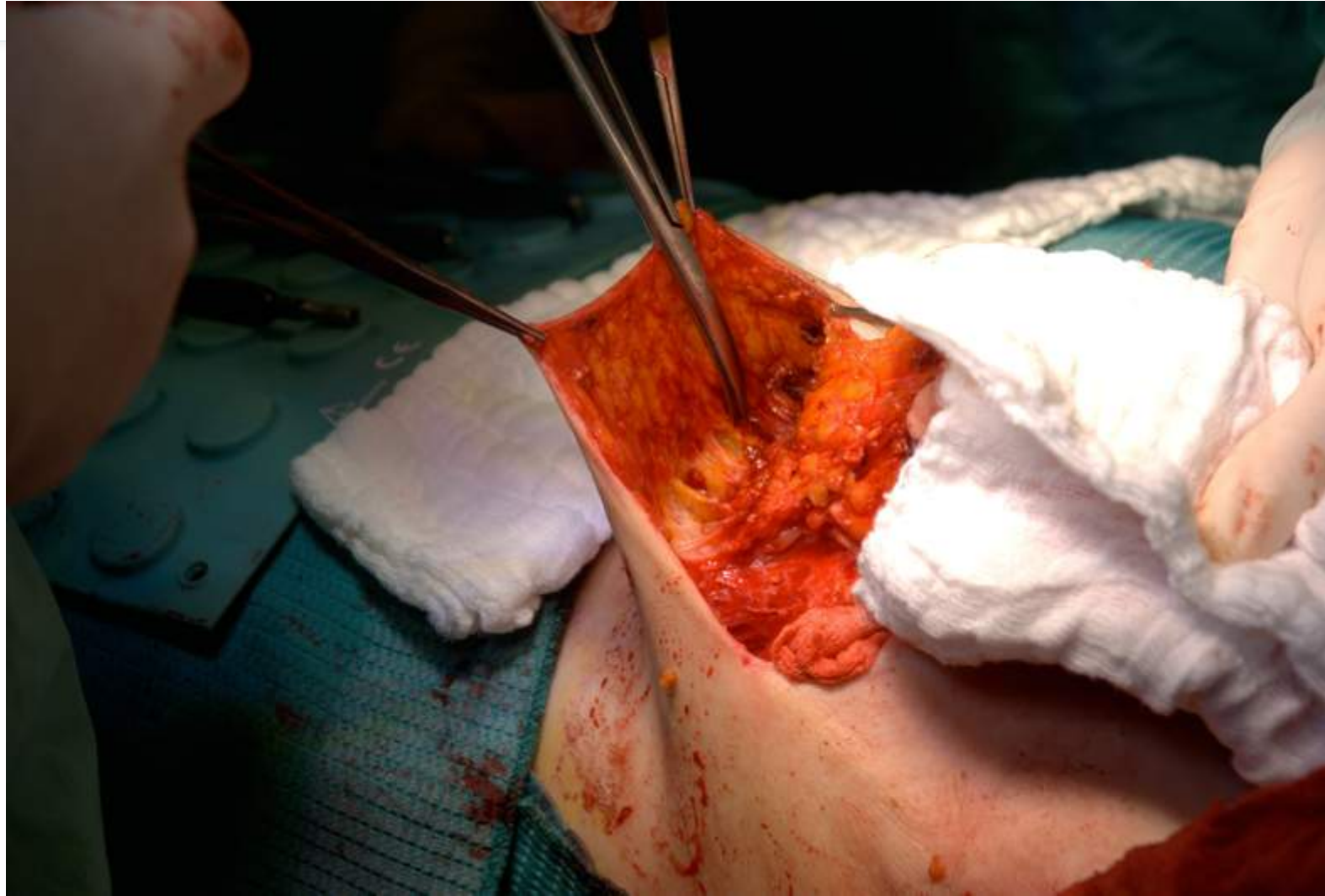
# Gland dissection



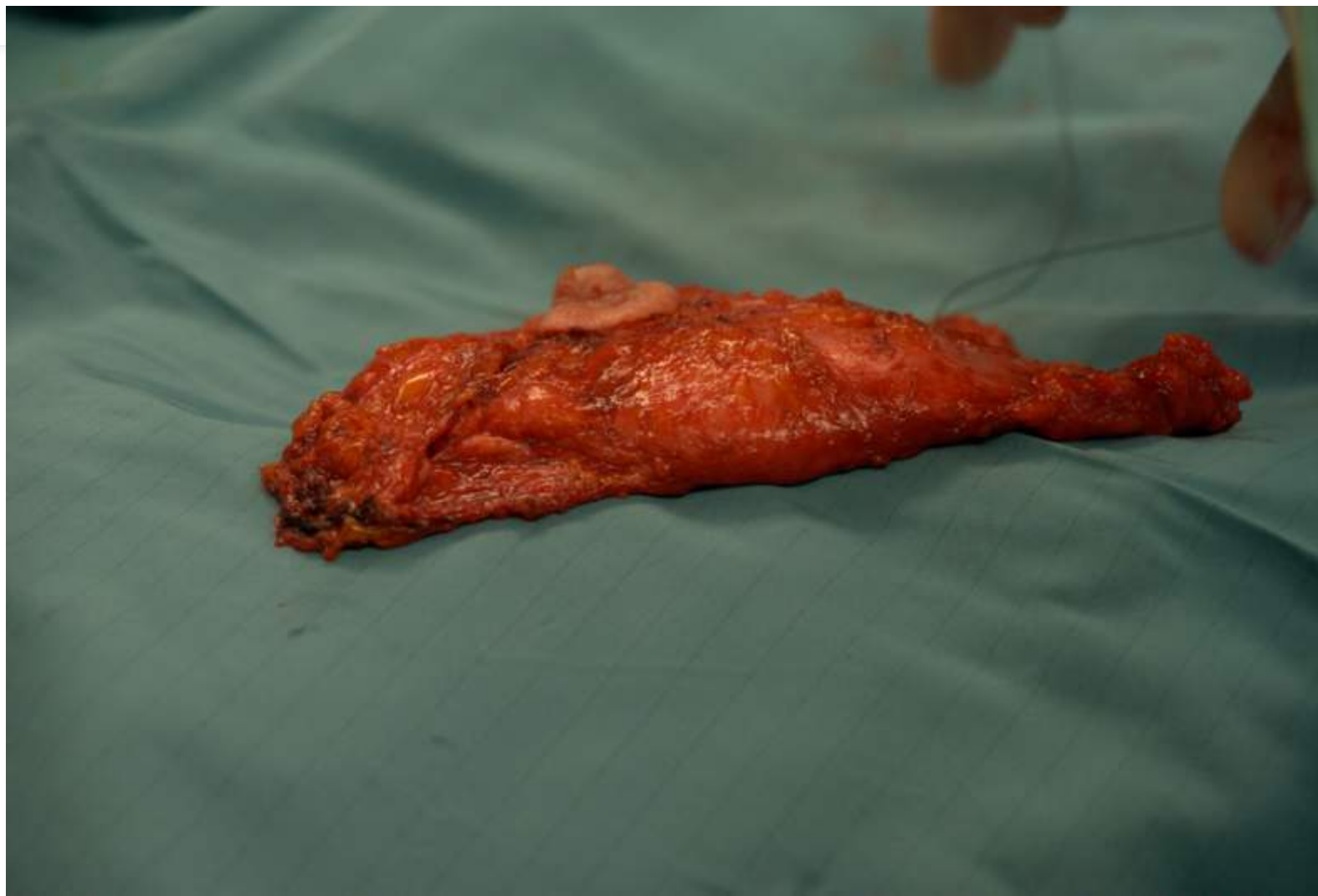# Gland dissection



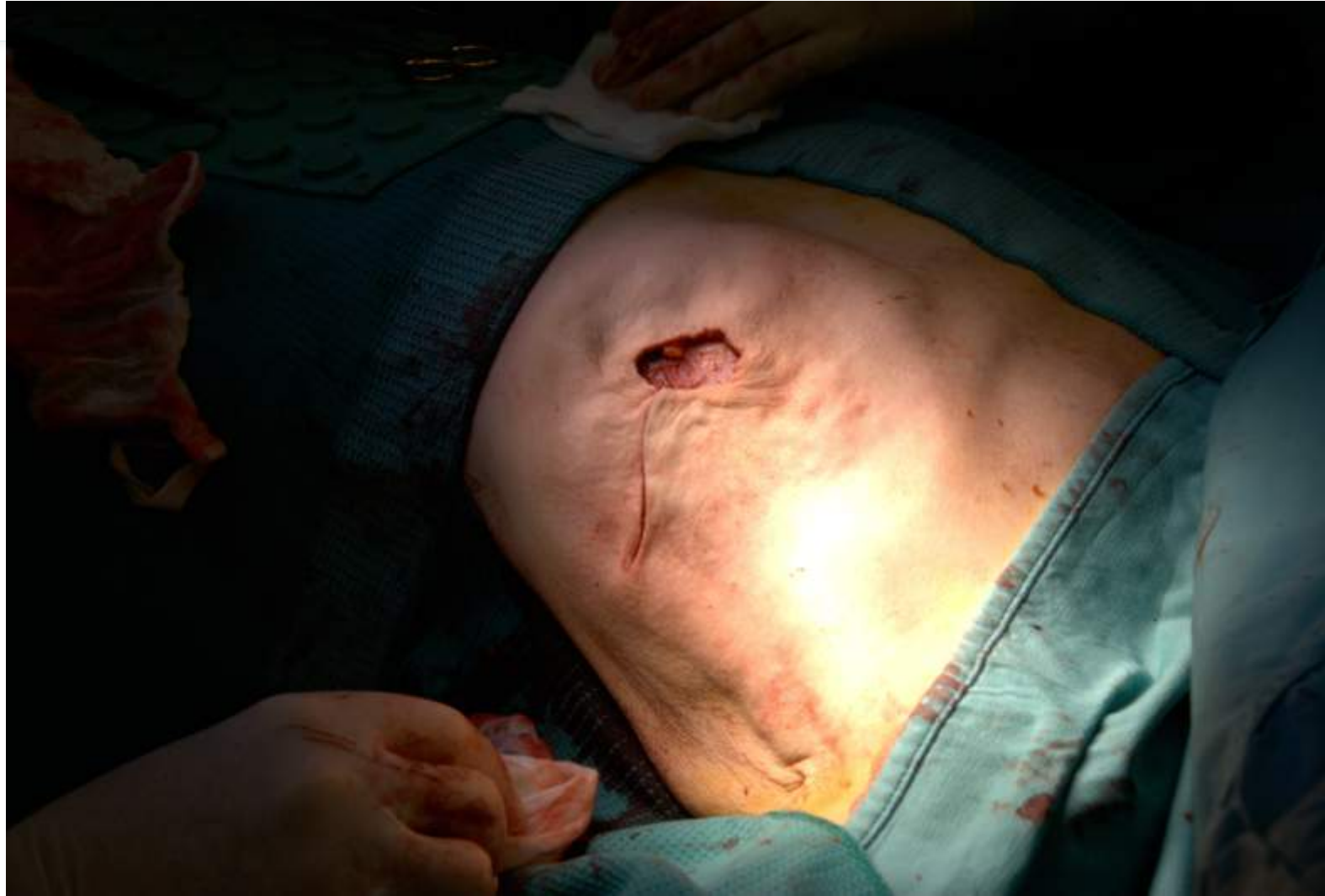# Gland dissection



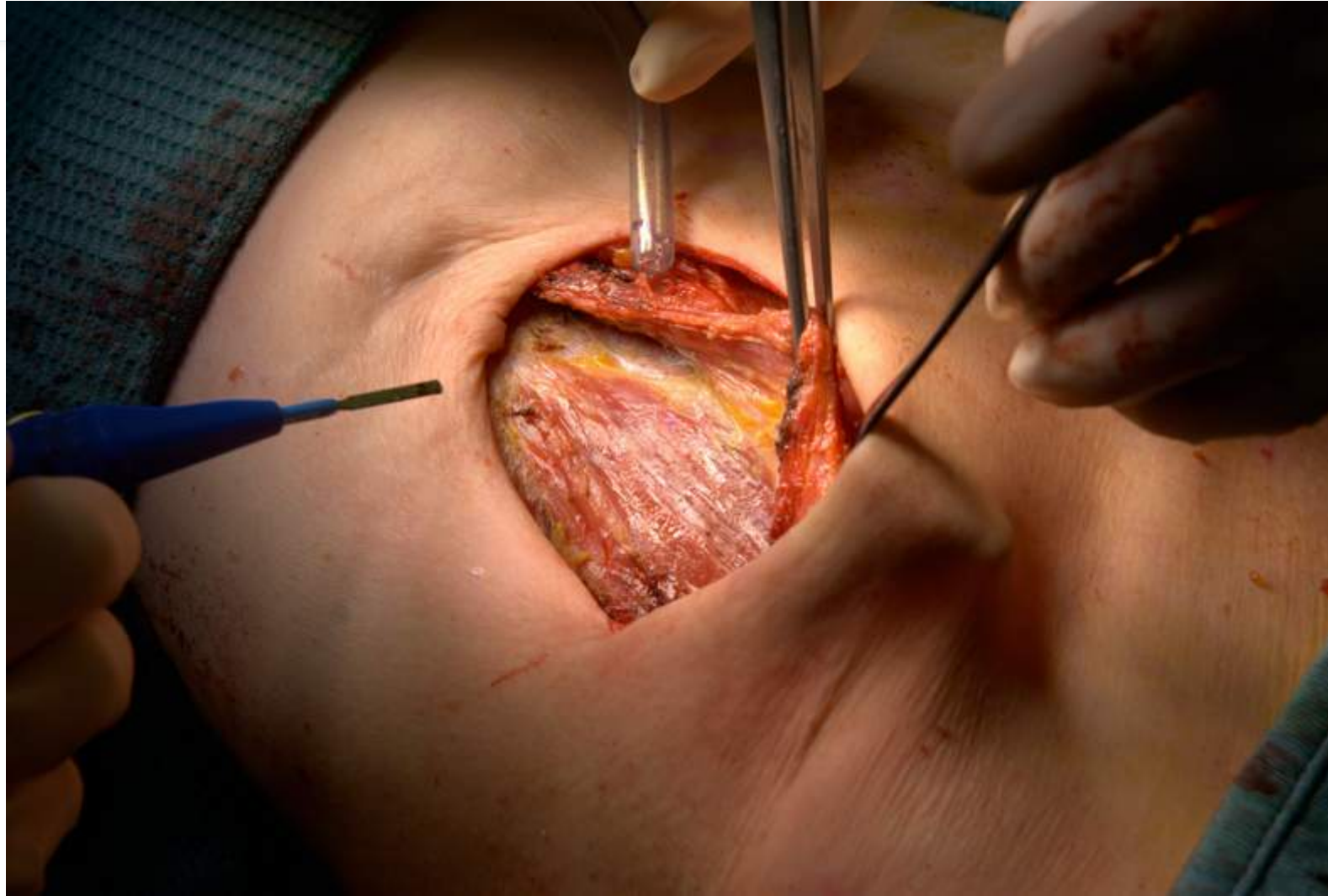
# Gland



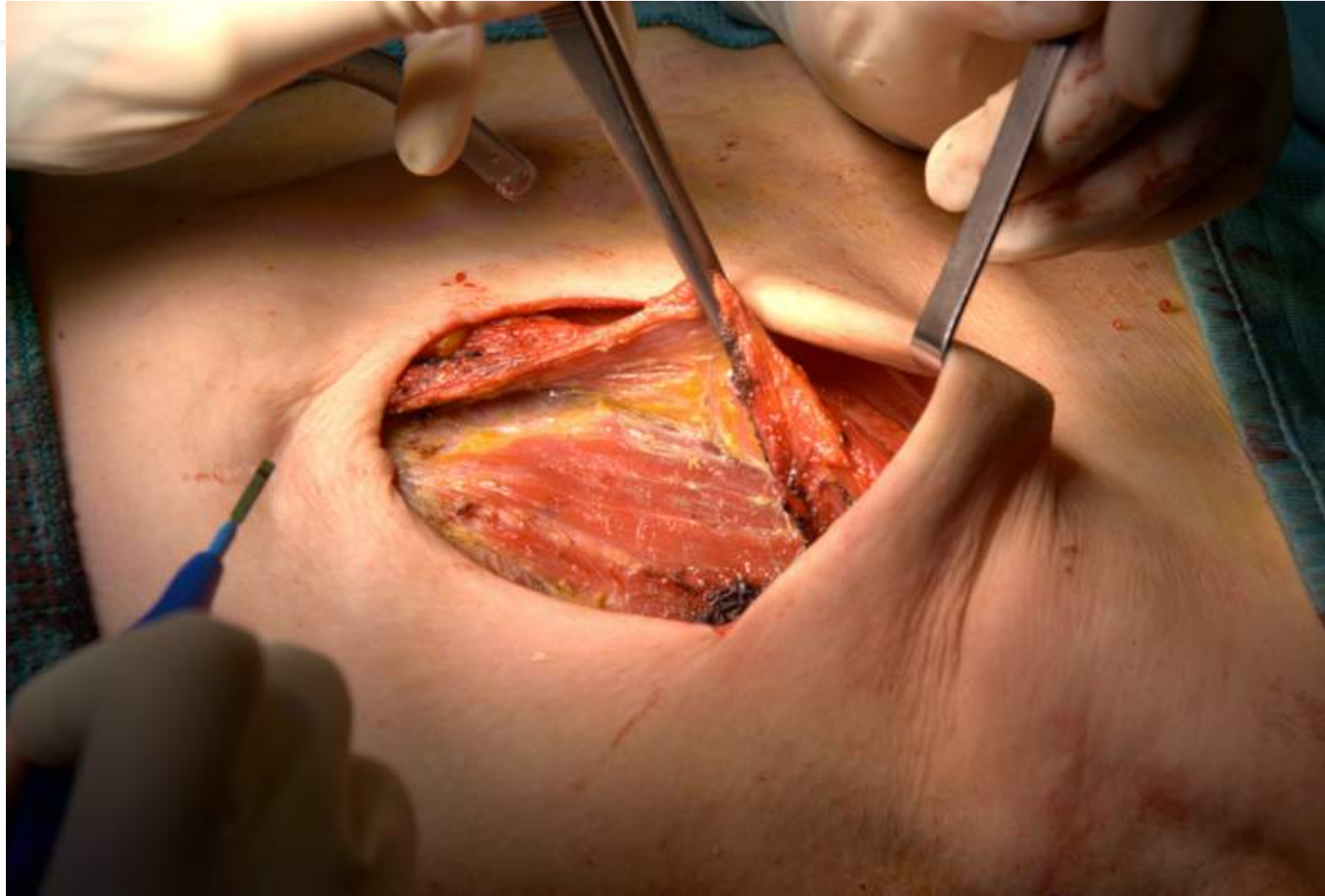
# Wide incision



# Pectoralis major muscle detachment

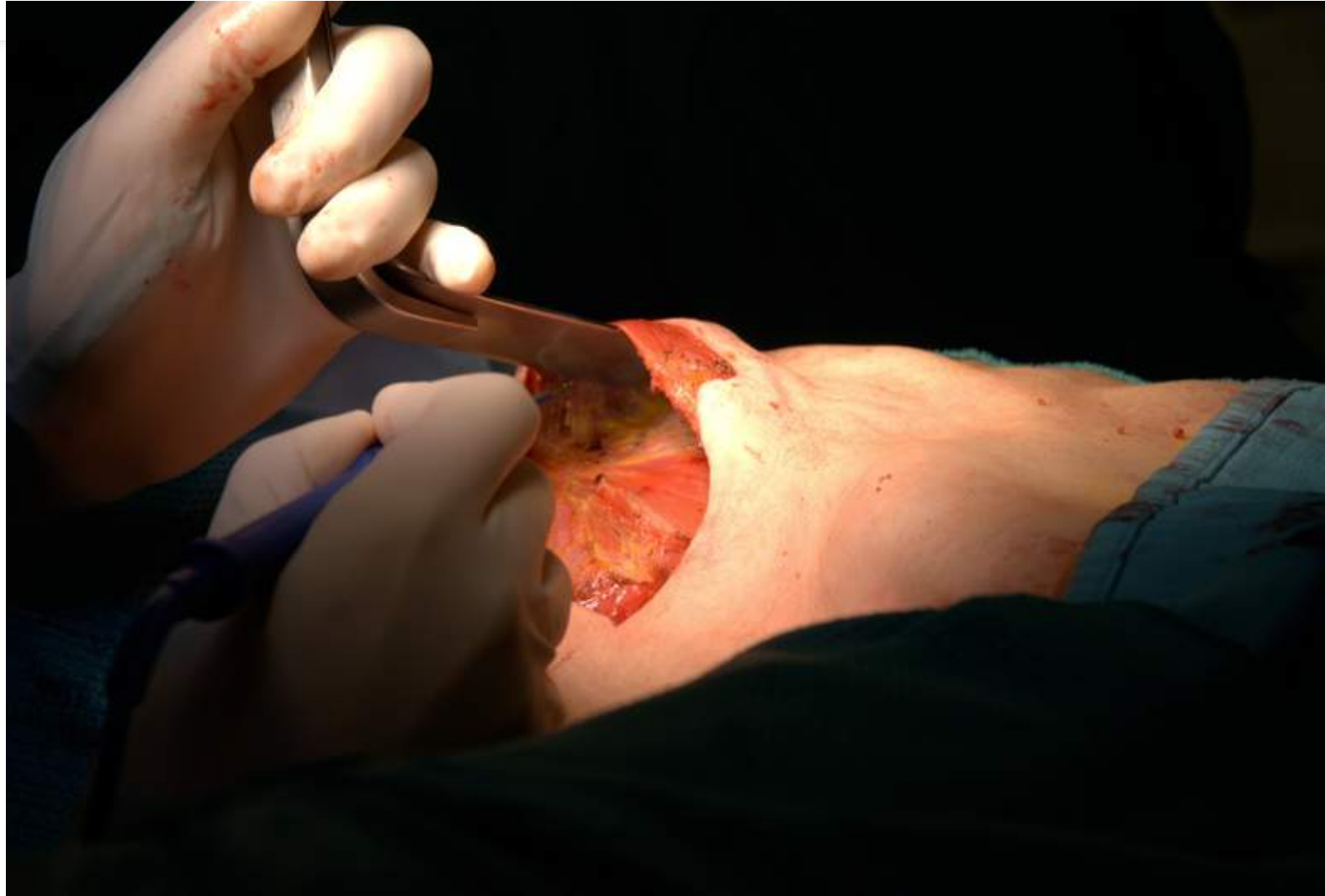

# Pectoralis major muscle detachment

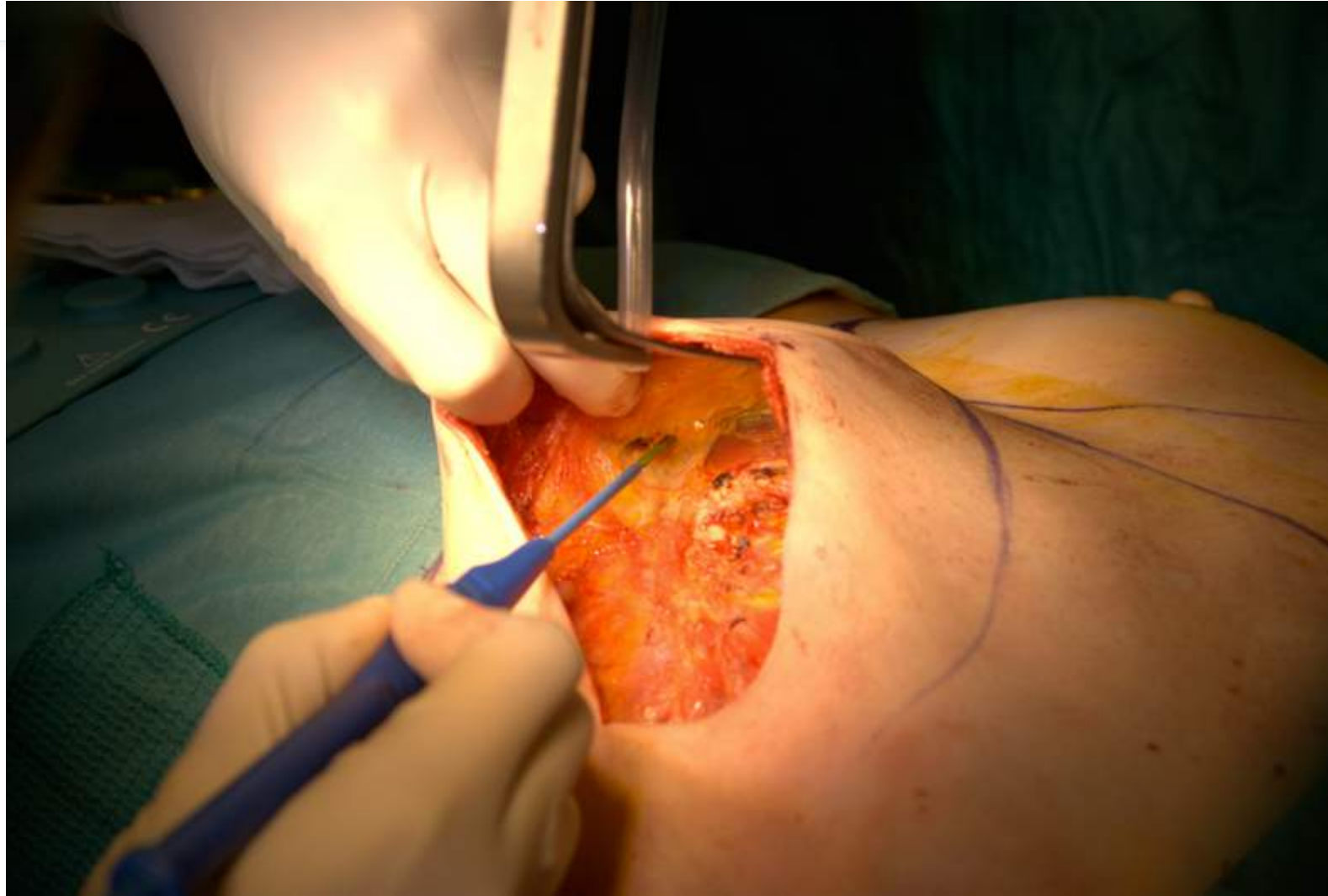




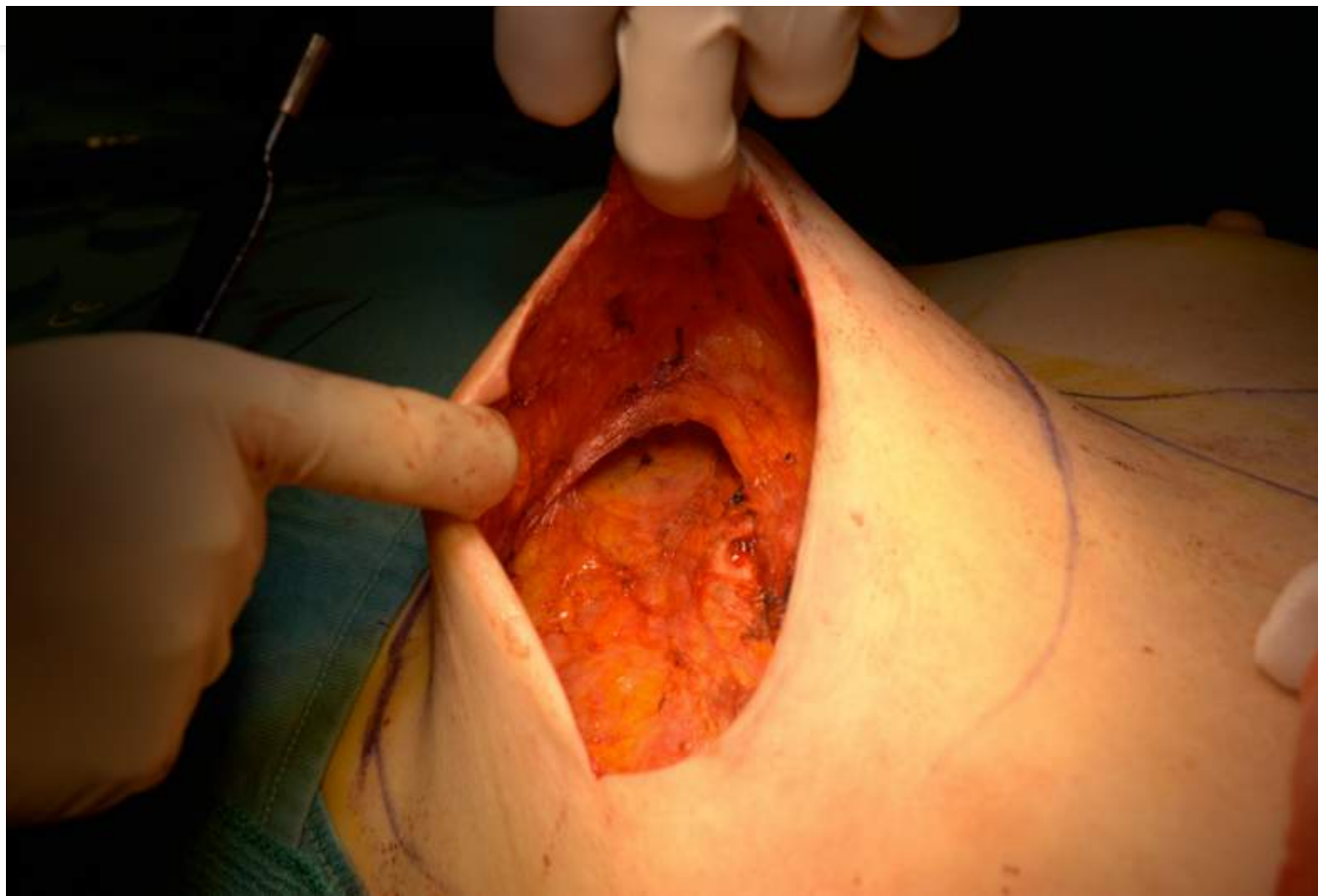
# Subpectoral pocket creation



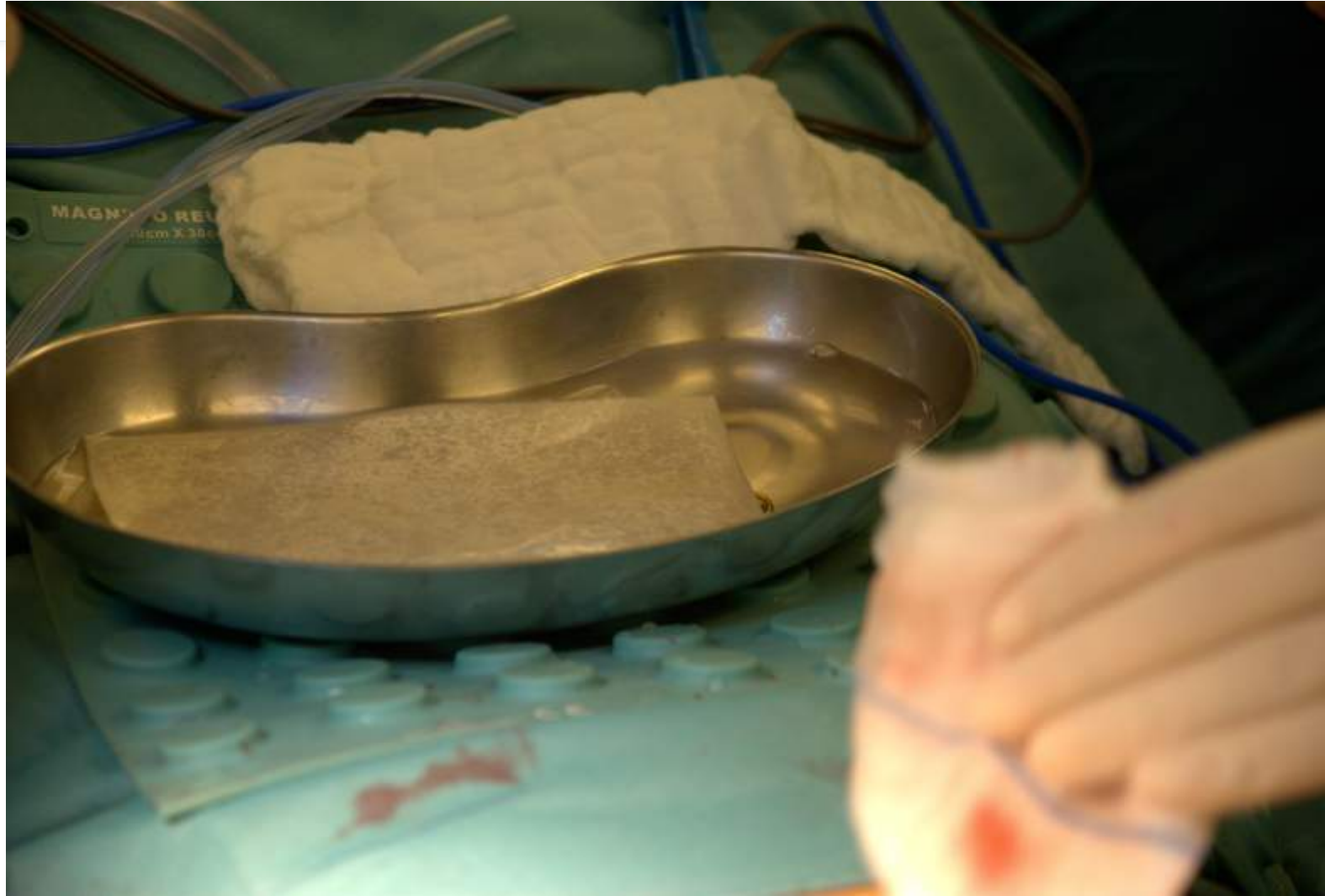# Subpectoral pocket creation



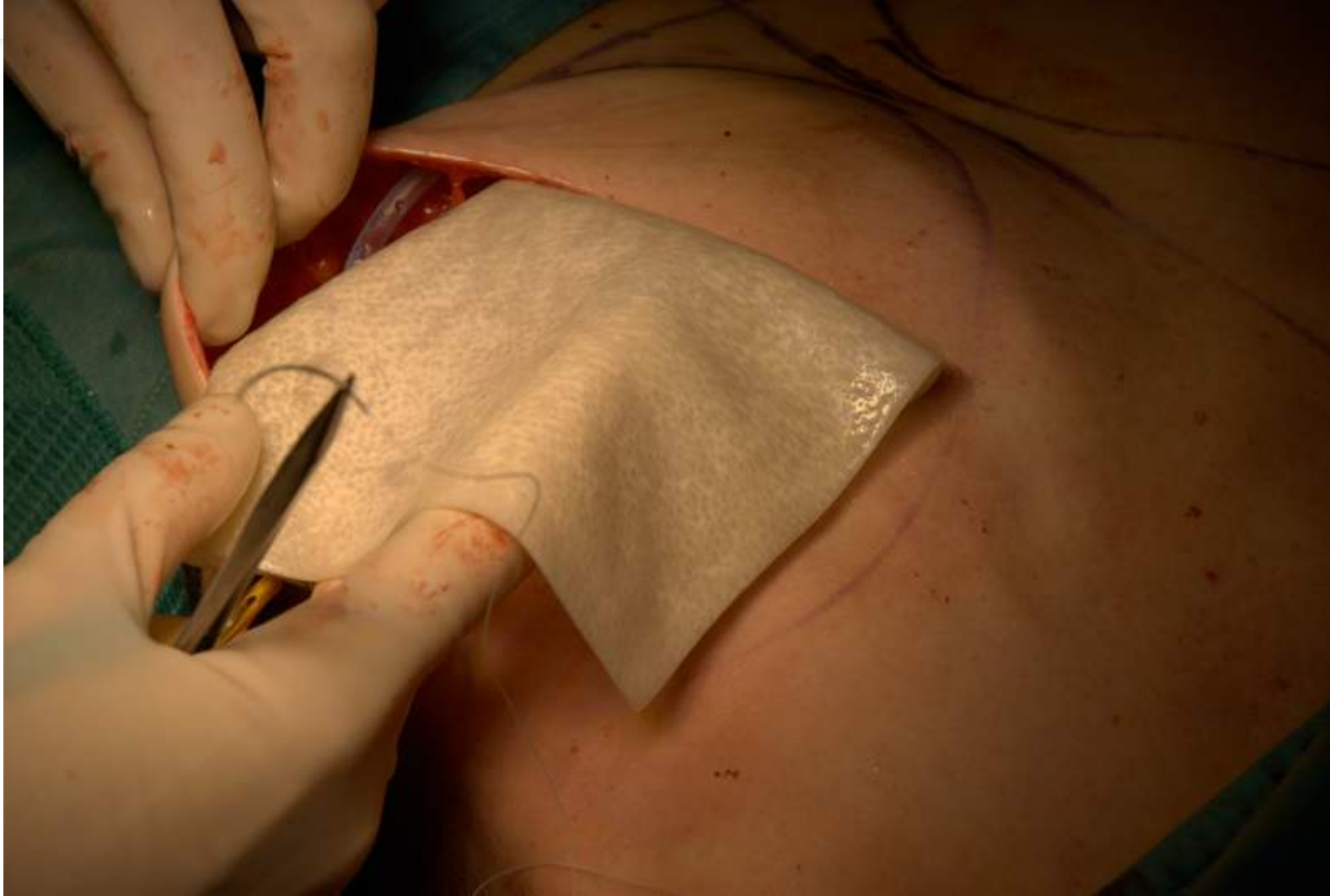# Defining inframammary fold



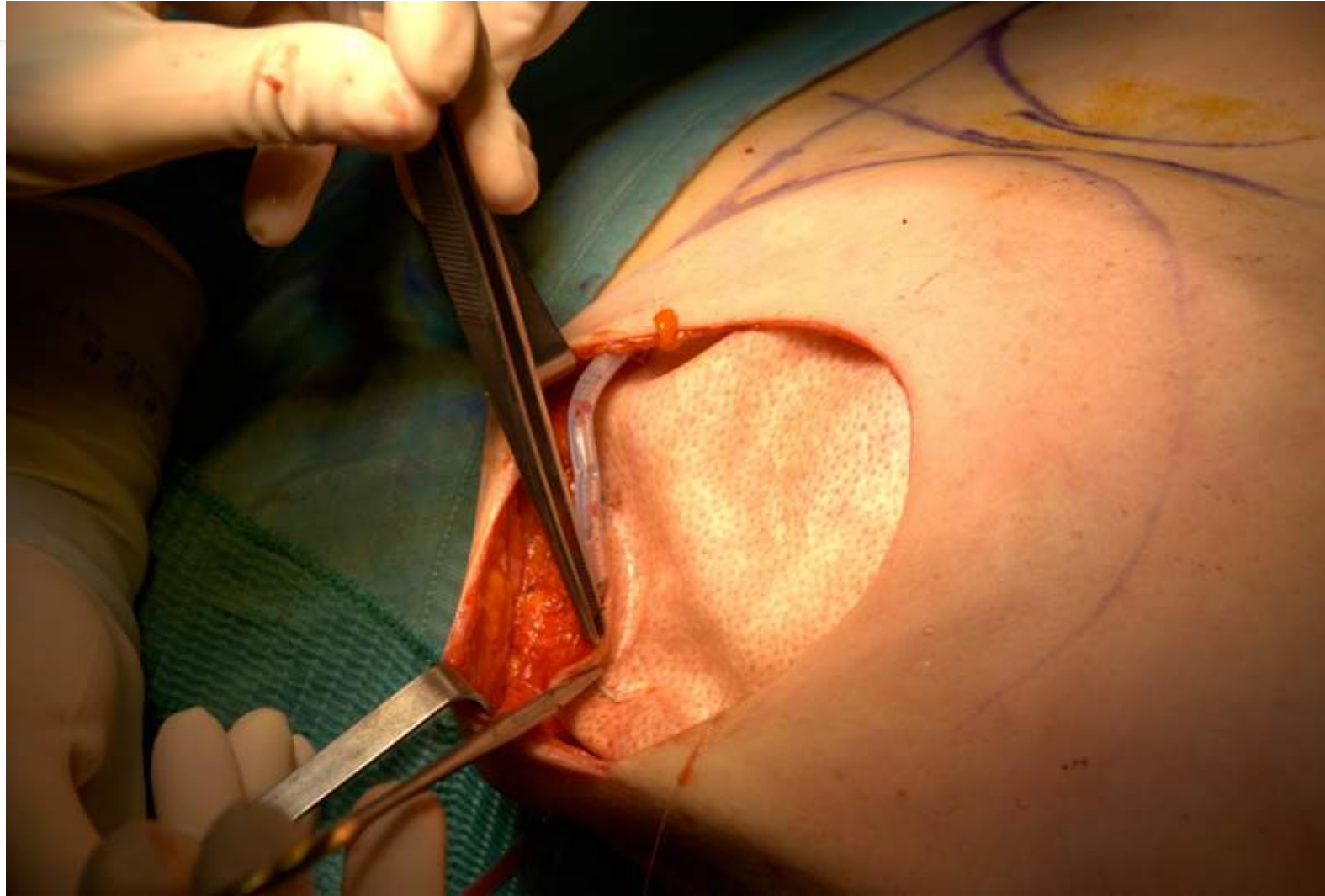
# Native® rehydration



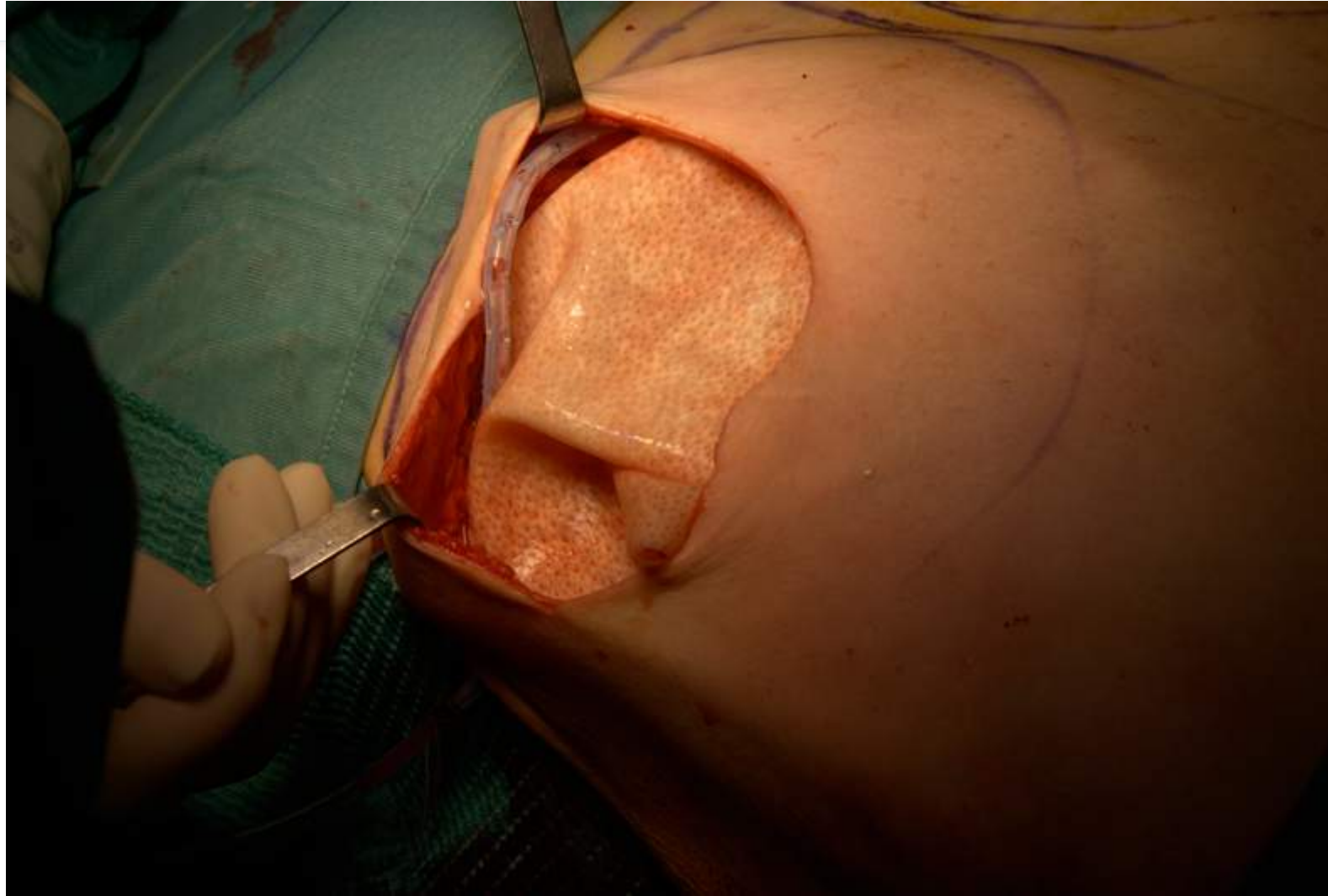
# Inserting Native® for pocket completion



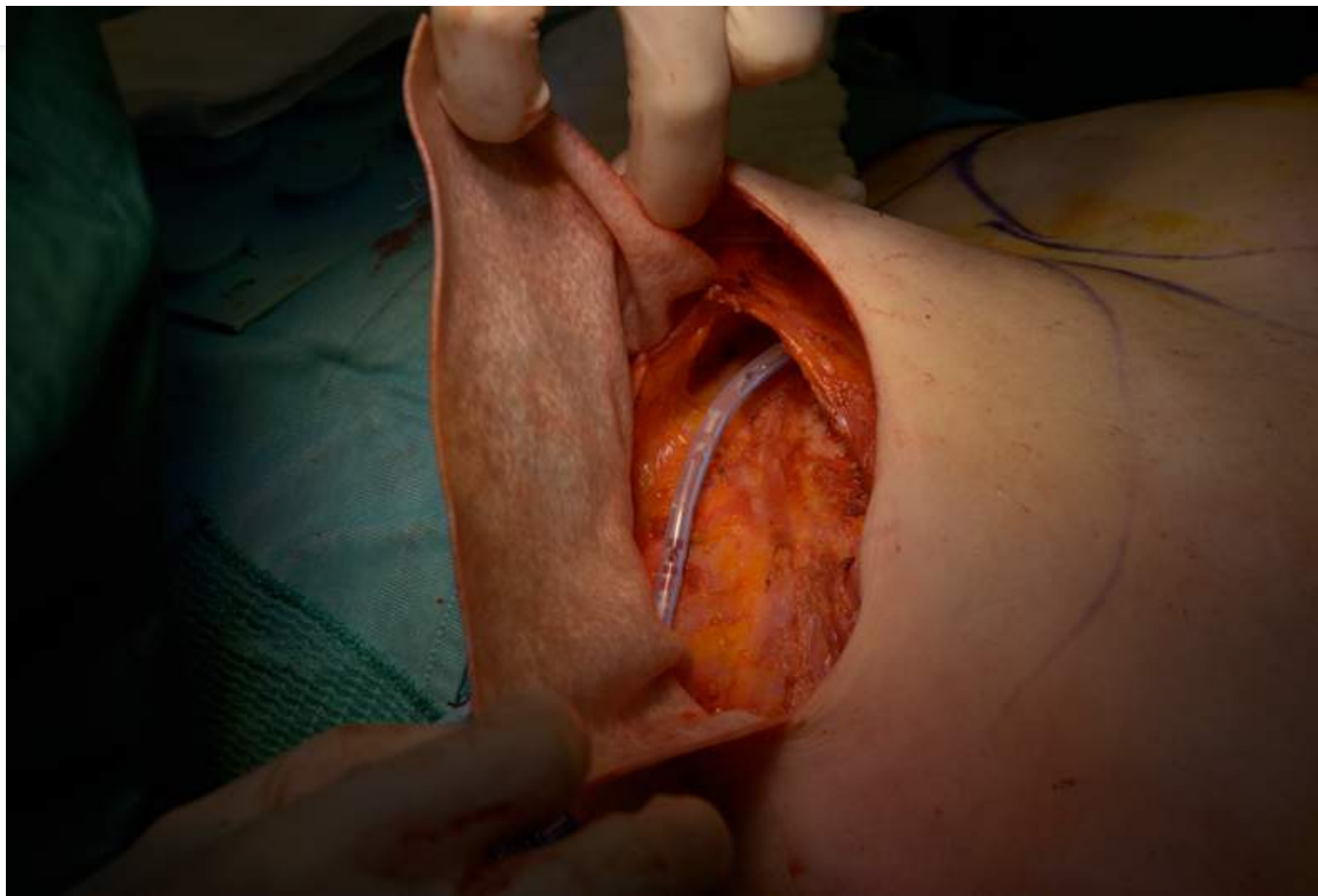# Suturing ADM to the IMF



# Suturing ADM to the IMF

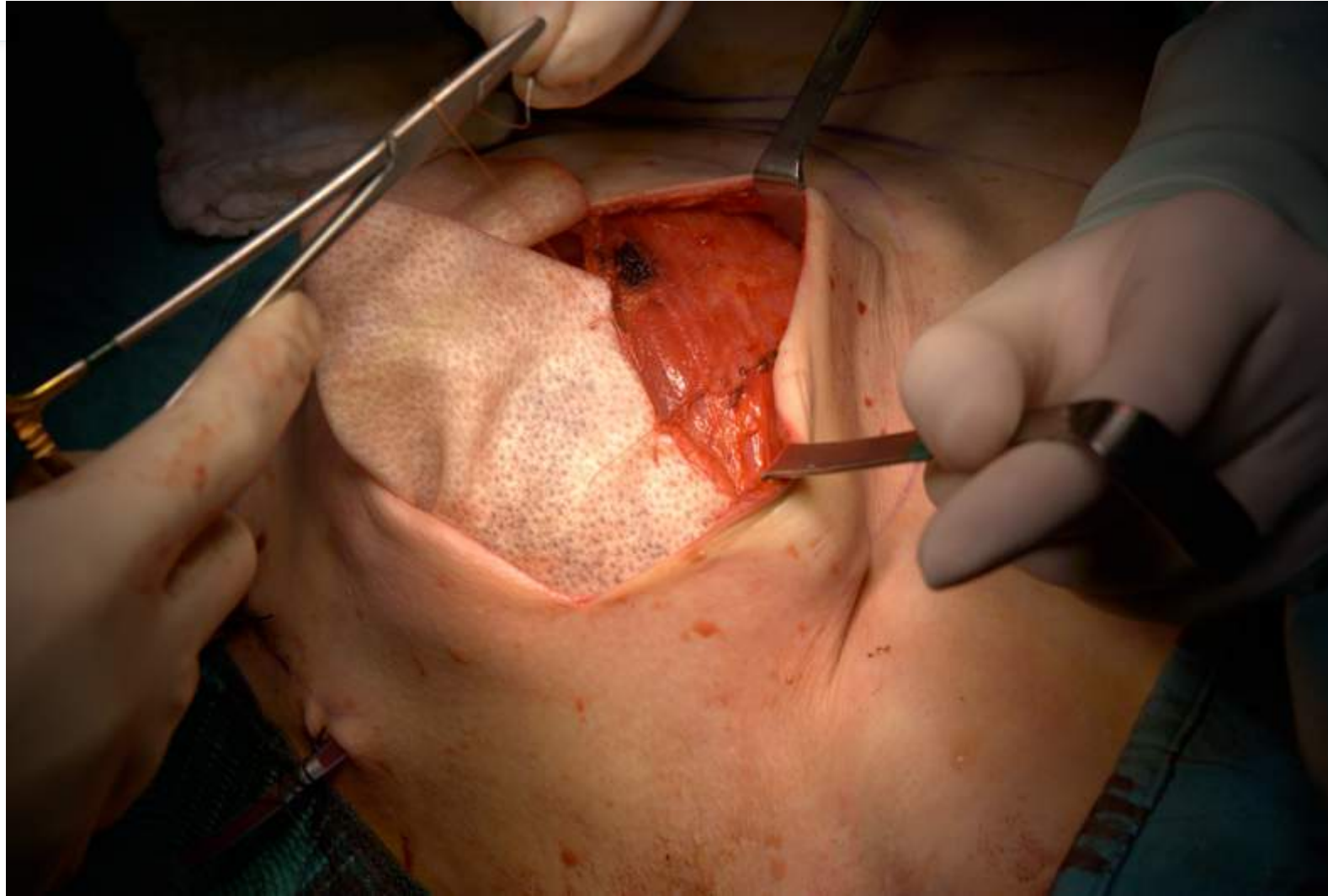


# Native<sup>®</sup> fixed to the IMF

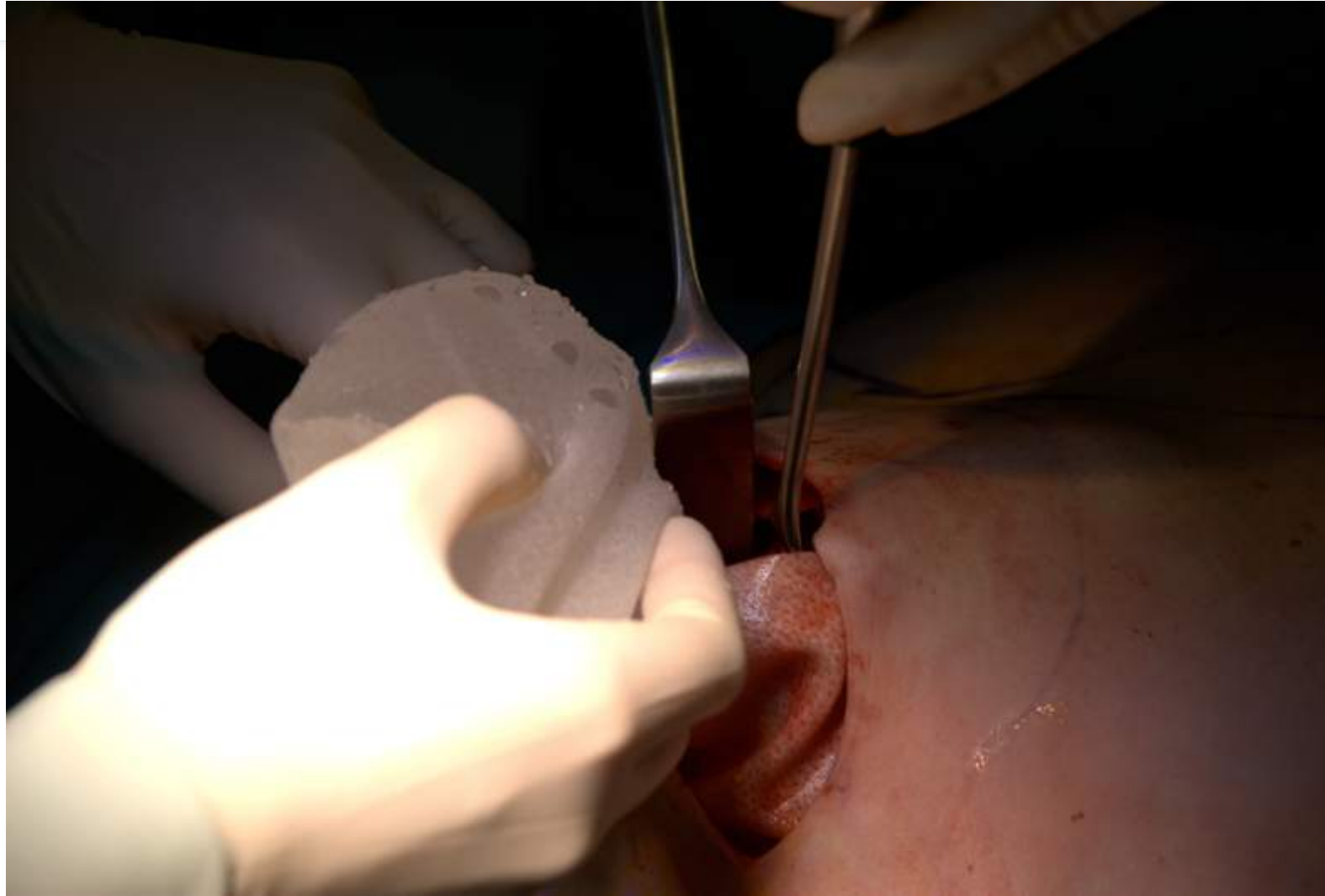




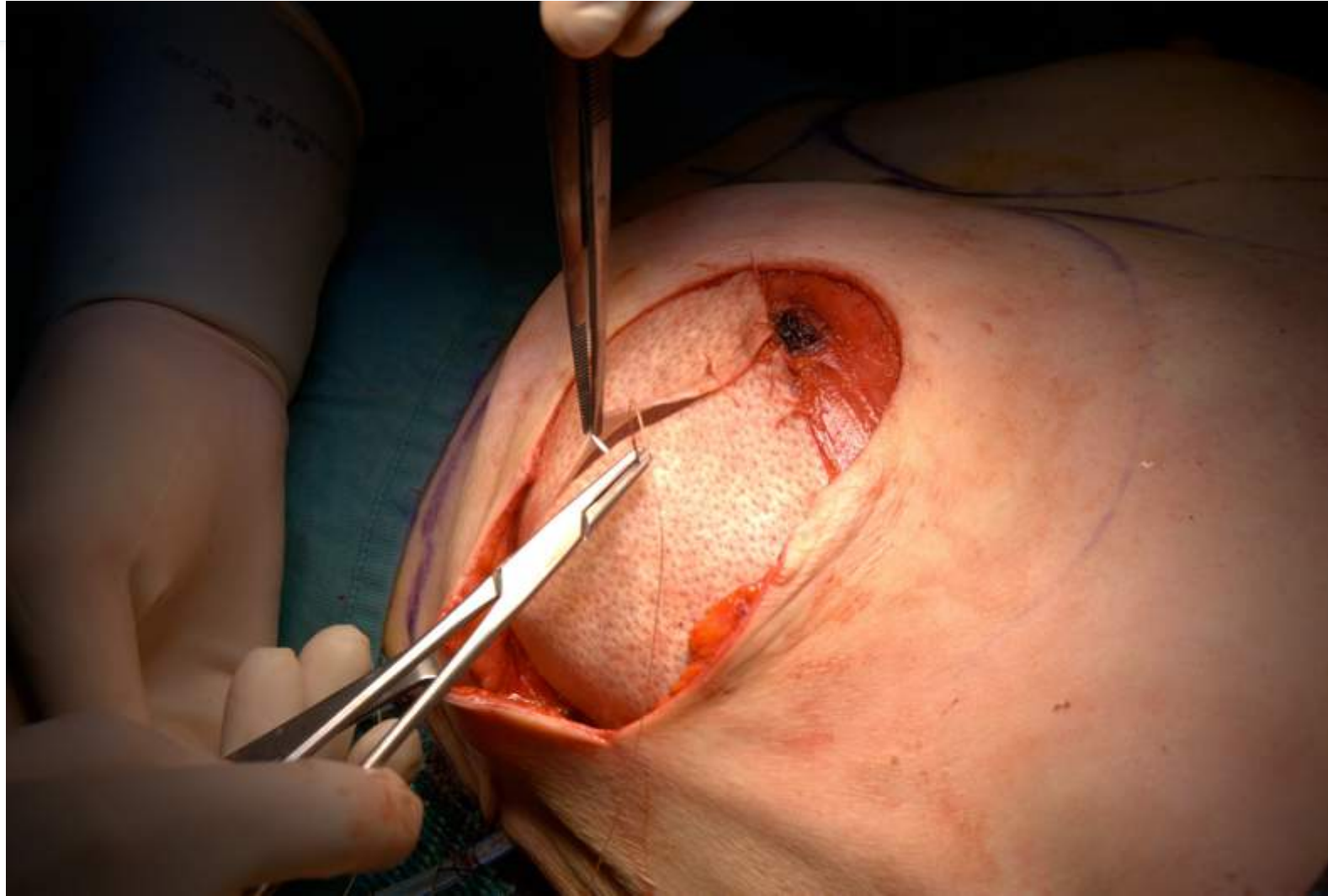
# Suturing ADM to the p.m.m.



# Breast implant insertion



# Dart or «*pince*» closure



# Skin closure



